Peter's tale

PETER RIMINGTON

Peter Rimington recounts his frightening experience of a heart attack, reminding us not to ignore any warning signs of risk. Cardiologist Nick Boon then explains how the modern treatment of acute myocardial infarction has transformed outcomes.

When my mother was 57 years of age she developed angina, and from then on would tell anyone nearby, usually some poor hapless waiter, that she was a 'heart case' and that the chef should use no butter when cooking for her. This produced either sly amusement or acute embarrassment in her family. Fourteen years later she had a triple bypass and went on to live another 14 years.

So I knew from the age of 27 that there was a family history of heart disease, but comforted myself that my father, who had always smoked like a chimney, had made it to 87 without a single hospital visit. I also knew that my cholesterol was high (7.5mmol/l) but I was not diabetic, was fairly fit (I ran four half-marathons a year), a non-smoker, led a non-sedentary lifestyle and was not hypertensive.

However, I had slowly gained weight over the past 10 years and, in spite of keeping active and taking part in charity cycle rides, was probably not as fit as I should have been. I had tried, unsuccessfully, to change my diet, as we South Africans tend to love our meat, butter and red wine!

In November 2013, I participated in the cycle ride in the Western Cape to raise funds for The Urology Foundation. This proved to be really tough going and I realised I was nowhere near as fit or slim as I had been kidding myself! On returning to England I weighed 109kg. I started a diet and exercise routine, which is exceedingly difficult in England in the winter. But it worked and in two months I had lost 10kg using the famous Kirby PLACE regimen.[1] And my resting pulse had come down to 60bpm.

I had noticed a big improvement in my cycling too, staying ahead of a friend up the dreaded Ditchling Beacon, a brutal hill in East Sussex. So the new theory of training while carrying a lot of extra weights may be correct!

In January 2014, however, while showering after a training session, I developed a rather unpleasant chest pain. At first I thought it was from the spin training, which includes press-ups, but it got worse and soon radiated up into the jaw and down the left arm. And I had a very unpleasant feeling of restlessness and a cold sweat. So it was clear I was having a heart attack. Believe me, you do not call it angina when it is happening to you!

I told my wife to call the ambulance and fortunately it arrived within five minutes. The crew gave me aspirin and oxygen, did an ECG to confirm a heart problem and texted that to the on-call cardiologist at the local cardiac centre. He advised immediate access to the cardiac catheter lab. Under local anaesthetic, they passed a catheter to the heart, found the blocked left anterior descending vessel, and sucked out the clot, which instantly relieved the pain. They could then see a single plaque that had ruptured, and put a stent over it. The 12-lead ECG reverted to normal immediately and an echo cardiogram two days later revealed no muscle defect. So within 90 minutes of first feeling any discomfort, I had been successfully treated. That makes me very lucky indeed! And within four weeks I am reassured that I can recommence training, albeit a little more slowly for a while.

Peter Rimington, *MB ChB, MMed (Urol), FCS, Consultant Urological Surgeon, East Sussex Healthcare NHS Trust*

Many people have asked me if I was scared at the time. To be honest, it was too painful to be scared; I was just trying to keep calm and breathe the oxygen and wait for morphine. My wife was frightened that her usually unperturbed husband was a pale,

clammy, sweating wreck on the floor, with the dog licking his ear!

So how has this left me feeling? Not depressed – just grateful that it happened in the UK and not in the wilds of South Africa! And I am in the fortunate position of having seen all the other cardiac vessels and I know they all look like six-lane highways. I can be confident of returning to strenuous training in the near future. And I have a huge motivation to achieve a target weight of 90kg. But it has taught me a lesson. If you have a well-known warning sign of possible risk, do not just pretend that nothing can happen to you. None of us is immortal – have yourself checked out and if something is found, be a patient. Take the advice of the experts and do as you are told. If I had lowered my cholesterol 10 years ago by diet or statins, this may never have happened.

REFERENCE

1. Kirby R. Getting to a better PLACE: helping patients counter obesity by achieving enduring lifestyle change. *BJU Int* 2011;107:873–4.

The cardiologist's comment

NICHOLAS A. BOON

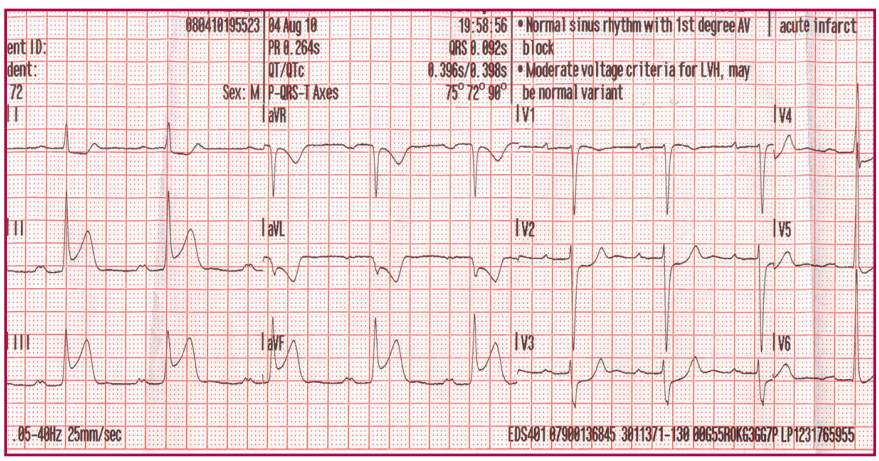

Figure 1. Presenting ECG of a 48-year-old man with an acute inferior myocardial infarction showing ST elevation in leads 2, 3 and aVF

Nicholas A. Boon, *MD, FRCP, Consultant Cardiologist, Royal Infirmary of Edinburgh*

Peter Rimington's graphic and very personal account of a modern heart attack describes an unexpected, potentially preventable, and very frightening event that was expertly treated and has probably left him feeling rather lucky, a bit chastened and absolutely determined to prevent a recurrence.

Figures 1 and 2 illustrate a similar case. Such stories are now commonplace and serve to remind us of how far we have

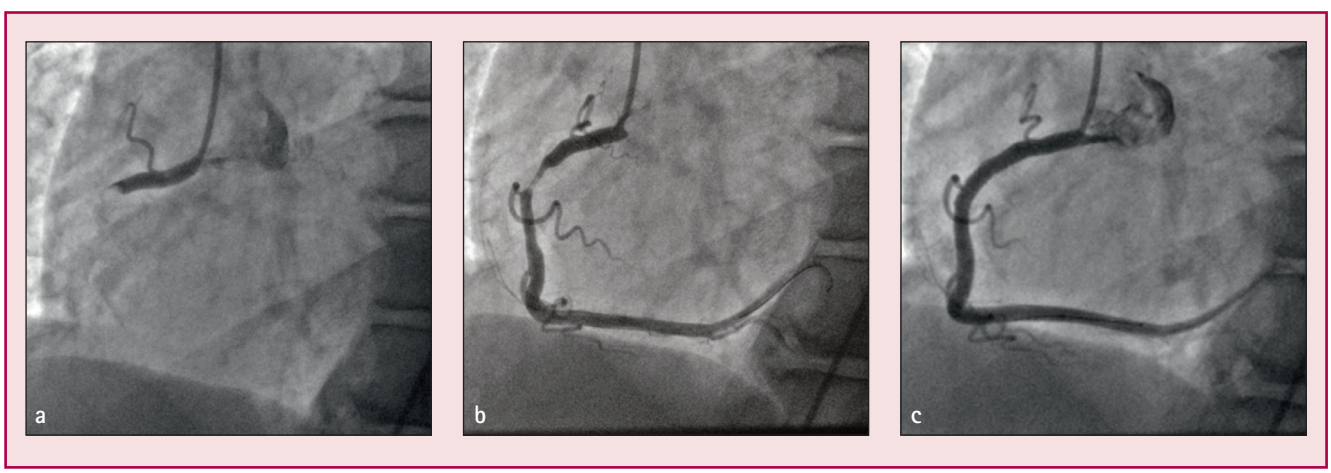

Figure 2. The patient described in Figure 1 was treated by primary percutaneous coronary intervention. Coronary angiography was undertaken, using the right radial approach, less than one hour after the onset of chest pain and revealed acute thrombotic occlusion of the right coronary artery (a), the thrombus was aspirated using a suction catheter, revealing the culprit stenosis (b), which was stented, resulting in a widely patent vessel (c) with normal flow

come since we used to treat heart attack by prolonged bed rest and nothing else.

There has been a huge fall in age-adjusted death rates from coronary artery disease in many parts of the world since those days, and it is clear that this has been driven by a combination of better prevention and treatment strategies, particularly the management of acute myocardial ischaemia.[1] The numerous changes in the way we treat acute myocardial infarction have all produced incremental benefits (Box 1), which added together have transformed outcomes (Table 1).

I am old enough to remember the days when patients with heart attack were treated by enforced rest, and recall how this approach would often make the survivors fearful of returning to work or undertaking any exertion; this effectively spawned the need for formal cardiac rehabilitation. By the time thrombolytic therapy was introduced, heart attack patients would often spend only a few hours in bed, but would typically feel bruised and shattered when they were discharged from hospital five or six days later.

BOX 1. Key milestones in the changing treatment of myocardial infarction

- Resuscitation
- Coronary care units
- Pre-hospital care
- Antiplatelet/anticoagulant drugs
- Beta-blockers
- Thrombolysis
- ACE inhibitors
- Statins
- Balloon angioplasty
- Stenting
- Thrombectomy

Primary percutaneous coronary intervention has transformed the patient experience and, as Peter describes so well, will usually result in rapid relief of pain and a full recovery. Indeed, in my experience, patients treated in this way will often ask to be discharged within an hour or two of the procedure and may need to be persuaded to consider lifestyle change and long-term drug therapy.

	1970	2010
Hospital mortality	35%	3%
Hospital stay	6 weeks	3 days
Long-term disability	Invariable	Rare
Return to work	<30%	>90%
Prognosis	Poor	Excellent

Table 1. Combined impact of improvements in treatment of myocardial infarction on outcomes

Peter quite rightly points out that if he had paid a little more attention to his cardiovascular risk in the past, all this might have been prevented. We will never know, but the good news is that he can do so now and most importantly can look forward to the future with real confidence.

REFERENCE

1. Nabel EG, Braunwald E. 200th anniversary article. A tale of coronary artery disease and myocardial infarction. *N Engl J Med* 2012;366:54–63.